

Technical Whitepaper

UltraSound ATtenuation Imaging Technology (USAT)

Li Shuangshuang & Li Jinyang

UltraSound ATtenuation Imaging Technology (USAT)

— A New Solution for Fatty Liver Quantitative Analysis

Li Shuangshuang & Li Jinyang

Introduction

As a vital organ of the human body, the liver plays a crucial role in vitamin metabolism, hormone metabolism, bile secretion, detoxification, and production of coagulation factors. Severe liver dysfunction is often fatal to the human body. Nonetheless, the majority of chronic liver diseases are often unnoticeable and easily neglected, resulting in long-term irreversible damage. Therefore, the early detection of liver diseases and the monitoring and management of chronic liver disorders have become the focus of ongoing research in clinical practice.

With a high worldwide incidence, fatty liver disease is a serious threat to human health with a pathological change caused by excessive accumulation of fat in liver cells as a result of a variety of conditions, including obesity, alcoholism, and diabetes. Persistent fatty liver may lead to steatohepatitis, liver fibrosis, cirrhosis, or liver cancer. In recent years, its prevalence is increasing across the globe and the younger age at onset, attracting widespread clinical attention [1-4]. In particular, non-alcoholic fatty liver disease (NAFLD, Non-Alcoholic Fatty Liver Disease) has become the most prevalent chronic liver disease in China and the major cause of abnormal liver biochemical markers in physical exams.

Conventional B-mode ultrasound is mostly based on the following characteristics to assess the grade of fatty liver: 1) steatosis causes more echo signals back to the transducer, creating the appearance of a “bright” or hyperechoic liver in

liver parenchyma; 2) fat also attenuates the beam which decrease the signal penetration to the liver parenchyma. It may cause image blurring in structures like intrahepatic vessels and liver diaphragm. As a qualitative and subjective diagnostic tool, B-mode ultrasound lacks sensitivity and specificity for detection of mild fatty liver. The proton magnetic resonance spectroscopy (H-MRS) can be used to determine the fat content in the liver, but it is not widely used owing to its expensive cost. In clinical practice, therefore, it is essential to develop an easy-to-use cost-effective technique for early quantitative diagnosis of fatty liver. As a result, CAP (Controlled Attenuation Parameter) has been developed based on a hepatic-oriented ultrasound equipment, which is also well-known for its transient elastography. By detecting the attenuation of ultrasonic echo, CAP can quantitatively detect and evaluate fatty liver, which is displayed together with the liver elastography results. It has been clinically proven that CAP can detect more than 5% of hepatic steatosis, with accurate differentiation between mild and moderate to severe hepatic steatosis [3-4].

Over a period of clinical use, however, physicians have gradually discovered CAP's high susceptibility to the operator's manipulation, liver scanning location, and planes, since CAP is calculated from the one-dimensional ultrasound signals obtained by the single-element probe, making it impossible to visualize the liver structure. Therefore, the reproducibility and accuracy of this quantitative method need to be further

improved. An accurate quantitative method that can provide visible liver structure and two-dimensional ultrasound attenuation data is urgently needed in clinical routine. In response to this demand, Mindray took the initiative to integrate LiSA (Liver Ultra-Sound Analysis) into its Hepatus non-invasive quantitative liver ultrasound machine, since LiSA can provide visual image guidance and two-dimensional ultrasound attenuation data; besides, its sensitivity and specificity in determining the staging of steatosis have been demonstrated by many clinical studies. [5-8]. However, owing to its reliance on dedicated probes and inability to generate ultrasound attenuation distribution images over a wide range, LiSA cannot fully meet the daily research needs of sonographers. As a result, technologies like ATI (Attenuation Imaging) and UGAP (Ultrasound-Guided Attenuation Parameter) have emerged in recent years which provide ultrasound attenuation images based on conventional convex arrays. As shown in some previous studies, these technologies outperform CAP in quantitative diagnosis [9-12].

In addition, more and more studies indicated [13-15] that fatty liver may also change other physical parameters of liver tissue, such as sound speed, in addition to ultrasound attenuation parameters. These physical parameters affect each other, and a single parameter may not be sufficient to fulfill all diagnostic needs. Therefore, new quantitative parameters are needed in clinical practice to better assist in the early assessment and staging of liver steatosis.

To this end, Mindray Resona R9 ultrasound system is equipped with Multi-parametric Fatty Liver Lab, an innovative multi-parametric quantitative analysis tool for fatty liver. This tool provides quantitative parameters at

different dimensions for fatty liver assessment, such as two-dimensional Ultra-Sound ATtenuation imaging technology (USAT), Radiofrequency based Hepato-Renal Index (HRI plus), Liver Texture Index (LTI), and Target Sound Speed Index (TSSI), so as to assist physicians in making a more accurate and reliable diagnosis through comprehensive analysis of the liver fatty infiltration. This paper introduces the principle and clinical application of the two-dimensional ultrasound attenuation imaging technology (USAT).

Ultrasound Attenuation Coefficient

When ultrasound signal travels in the tissue, its energy decreases due to the increasing tissue thickness, known as sound attenuation. Meanwhile, sound attenuation is also affected by the ultrasound frequency: the higher the ultrasound frequency is, the faster its energy lose. Studies have shown that fatty liver may accelerate the ultrasound energy loss in the liver, which is associated with an increased sound attenuation.

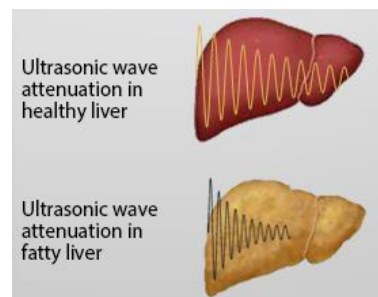


Figure 1. ultrasound attenuation of fatty liver

Under ideal conditions, ultrasonic signal propagates over a distance d in uniform tissue, its amplitude P can be approximately expressed as $P(d) = P_0 e^{-\alpha f d}$, where P_0 is the initial sound pressure when $d = 0$, α is the ultrasound attenuation coefficient (in dB/cm/MHz), and f is the frequency (in MHz). Therefore, for an ultrasonic signal with a

certain frequency, the sound energy intensity (in dB) decrease nearly proportional to the propagation depth (in cm), as shown in the Figure 2. The ultrasound attenuation coefficient of liver tissue is typically in the range of 0.4–1.0 dB/cm/MHz.

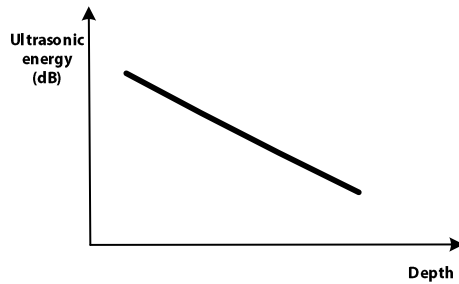


Figure 2. Energy loss with propagation

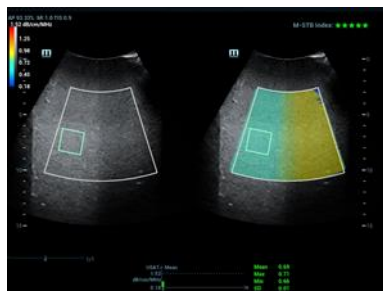

Figure 3. Different attenuation in the left and right regions with different tissue composition

The ultrasonic signal propagates through different types of tissues in the human body, such as fat layer, liver capsule, and blood vessels, resulting in reverberation or reflection. According to the characteristics of fatty liver disease, the ultrasound attenuation coefficient for each local position is calculated and displayed in a color-mapped image. As shown in Figure 3, when the degrees of steatosis vary across different regions obviously, the attenuation difference can be observed in the color-mapped image.

What's more, ultrasound attenuation coefficient was, somehow, calculated based on conventional B-mode images, especially on

some early-stage ultrasound platforms. In order to improve clinical images quality, conventional ultrasound platforms usually enhance the attenuated echo signals to a uniform image by focus or depth compensation that changes actual information, which cannot be recovered simply by adjusting time gain compensation (TGC) or image brightness using gain. Meanwhile, changes in the thickness of subcutaneous fat or in percentage steatosis may alter the propagation speed of ultrasonic waves in tissues, as well as the received ultrasonic echo signals. USAT could reconstitute the local information of ultrasonic signals accurately and reproducibly, such as sound speed and attenuation. It has been developed on Mindray Resona R9 platform with patented Full Space Restitution Technology based on raw ultrasonic RF signals, including special purposed focus control, beamforming, and signal processing algorithms.

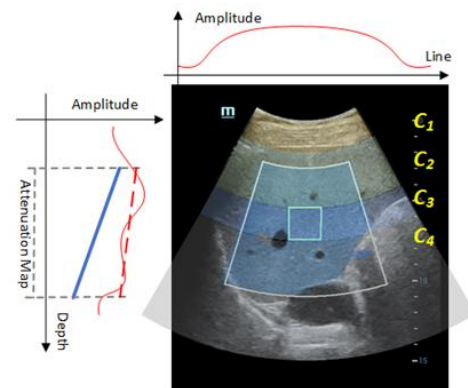


Figure 4. Full Space Restitution Technology

Particularly, as the ultrasound attenuation coefficient is related to the frequency determined upon its ultrasound emission, USAT can convert attenuation coefficient α (in dB/cm/MHz) to ultrasound attenuation rate $\alpha_1 = \alpha f$ (in dB/m) at a given frequency, which is convenient to compatible researches about both two common measurement units of

The other is the *USAT measurement phase*, in which the probe sends ultrasonic waves to the target tissue to calculate the ultrasound attenuation coefficient and generate images. After the ROI position confirmed, press the UPDATE button to start USAT measurement simply, then it will be automatically frozen and display the ultrasound attenuation images and measurement results simultaneously, as shown

in Figure 7.

USAT also provides reliability map (RLB MAP), a Mindray-exclusive tool that assists users in image quality control and evaluation. The map is displayed with the ultrasound attenuation images on the same screen, with the green and purple areas respectively indicating high and low reliability of imaging results. To allow the users to see the images intuitively, the purple area or the area with poor reliability in the ultrasound attenuation images may be hollowed out automatically as prompted by the reliability map, and only the results with high reliability are displayed.

After the measurements are acquired, the position and size of the green ROI can be adjusted by pressing the "SET" button to update the measurements of another region, as shown in Figure 8.

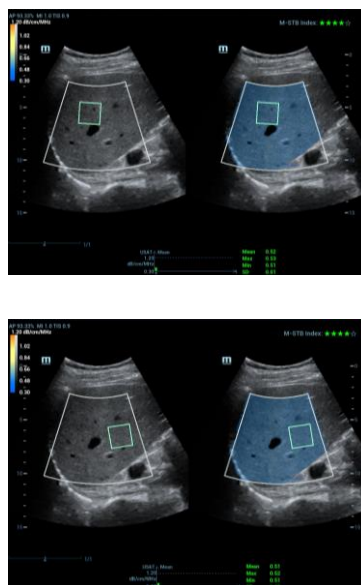


Figure 8. ROI Position changes after acquired

USAT Research Tools

USAT provides a variety of innovative, effective measurement tools to enable more flexible research and diagnosis for physicians.

[Selection of acquisition modes]

Typically, in order to improve the accuracy of clinical quantitative measurements, some physicians perform repeated single frame measurements and calculate the average value as the final measurement results. Preferably, at least 5 individual measurements are recommended. An alternative acquisition mode – Multi frame acquisition mode is offered for catering different user preference. For example, in the "single" mode, the image will be frozen automatically once a single frame has been acquired while in the "3 second" mode, the image will be frozen automatically after three seconds of consecutive acquisition completed. At that point, the system will continuously store multiple frames of images, display multiple measurements simultaneously to analyze and compare, as shown in the Figure 9.

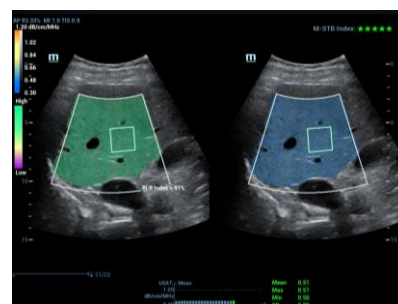

Figure 9. Multi frame acquisition mode

[Selection of statistical method]

Two types of statistical methods are available when USAT is applied in the assessment:

One is in the spatial domain. Based on the evaluation of the spatial uniformity within the local ROI, USAT may provide multiple spatial distribution statistics within the local ROI, including: mean (**Mean**), maximum value (**Max**), minimum value (**Min**), and standard deviation (**SD**), as shown in the Figure 10. Physicians may choose different quantitative

parameters in clinical research to compare the sensitivity and specificity in early diagnosis of fatty liver.



Figure 10. Spatial statistics within the ROI

The other is in the time domain. In cases where multiple repeated acquisitions are performed in a row for the local ROI, USAT may provide statistics for multiple acquisitions, including: median (**Median**), interquartile range (**IQR**), average (**Average**), standard deviation (**SD**), and **IQR/Med** or **SD/Avg** ratio representing the stability among multiple measurements, as shown in the Figure 11. By default, the Mean value in the internal spatial domain of the ROI is used for multiple statistical calculations.

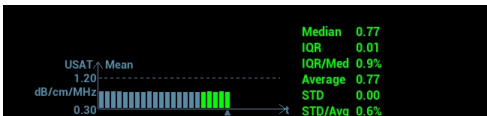


Figure 11. Multiple Acquisitions Statistics

[Measurement report]

The measurement results and images of USAT will be recorded in the report, as shown in the Figure 12. Physicians may also analyze and process the measurements in the report.

In addition, chronic disease monitoring and management for fatty liver may be performed on the same patient at different clinical stages. To this end, the patient's prognosis can be easily determined using the "Trend Chart" tool in the report, as shown in the Figure 13.

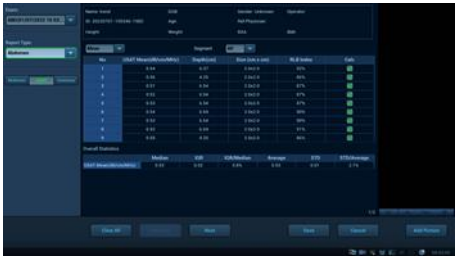


Figure 12. Measurement Report

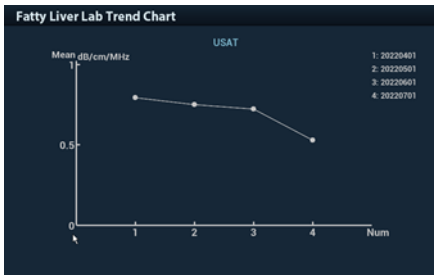


Figure 13. Trend chart

Case Study — Application in Fatty Liver

Mindray's USAT was applied in 45 patients with liver disease in a preliminary clinical study in which two physicians with more than 10 years of experience in ultrasound operations performed USAT and ATI (Aplio i800, Canon Medical) measurement and steatosis grading based on B-mode imaging. At least 5 valid measurements were obtained from each patient. According to the study results, USAT is of great clinical value in non-invasive quantitative diagnosis of fatty liver, which is highly consistent with both steatosis grades based on B-mode imaging and similar measurements, it also demonstrates good measurement stability and user-friendliness.

The figure below shows the relationship between the USAT and ATI measurements, with a correlation of **86%**. Besides, USAT measurements show good reproducibility, with a coefficient of variation **< 6%** (**SD < 0.04 dB/cm/MHz**). Moreover, the USAT results also show excellent inter-observer consistency,

with a correlation coefficient between the two operators of **0.9**.

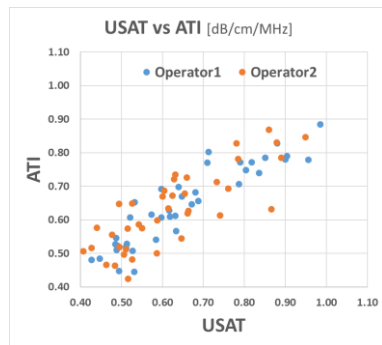


Figure 14. Relationship between USAT & ATI

USAT provides good consistency with steatosis grading based on B-mode imaging, demonstrating its great potential to help determine the stages of fatty liver, as shown in the figure below, the mean values of USAT in different steatosis grades based on B-mode imaging were **0.49, 0.59, 0.70, and 0.90 dB/cm/MHz** respectively. It can be seen that USAT measurements increase with the progression of fatty liver. Steatosis was categorized based on Brunt grading as follows: S0 < 5%, S1 = 5% -33%, S2 = 34%-66% and S3 ≥ 67%. The recommend cutoff value of USAT, as shown in Table1, are 0.53, 0.66, 0.82 dB/cm/MHz respectively.

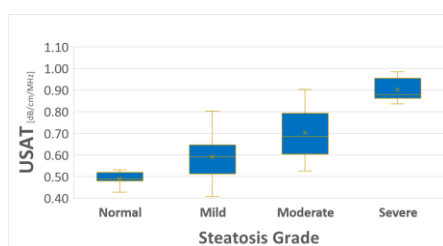


Figure 15. USAT values in each steatosis grade

steatosis ≥ 5% (≥ S1)	≥ 34% (≥ S2)	≥ 67% (S3)
0.53	0.66	0.82

Table 1. USAT cutoff values (dB/cm/MHz) for the prediction of ≥S1, ≥S2 and S3 steatosis

With the help of ultrasound attenuation images in clinical practice, physicians may select highly reliable areas for quantitative measurements and intuitively determine the degree of fatty liver based on the image color. Figure 16 shows the typical USAT images of patients with normal liver, mild fatty liver, moderate fatty liver, and severe fatty liver. The image color changes from blue to orange-red with the progression of fatty liver. The users may also use a different color map or adjust the quantitative scale of the map to improve contrast.

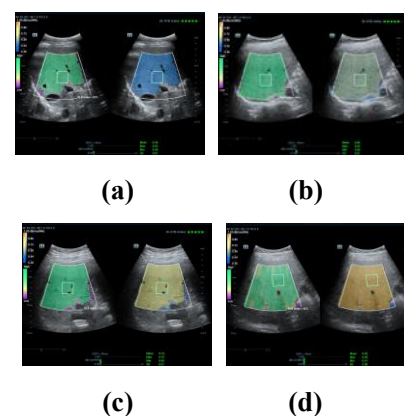


Figure 16. USAT images in each steatosis grade: (a) normal; (b) mild; (c) moderate; (d) severe

It is worth noting that clinicians have long been troubled by the poor measurement stability or repeatability of conventional quantitative liver imaging technology. For instance, the quantitative results of CAP measurement may vary due to the differences in operating procedures, intercostal spaces, or respiratory conditions of patients. The innovative "Full Space Restitution Technology" of USAT increases the repeatability of measurements in different views, while lowering the complexity of operation for beginners as well as the difficulty in examining patients who can hardly hold their breath. As shown in Figure 17, the measurements of the liver parenchyma remain stable despite significant changes observed in

the liver views in the B image.

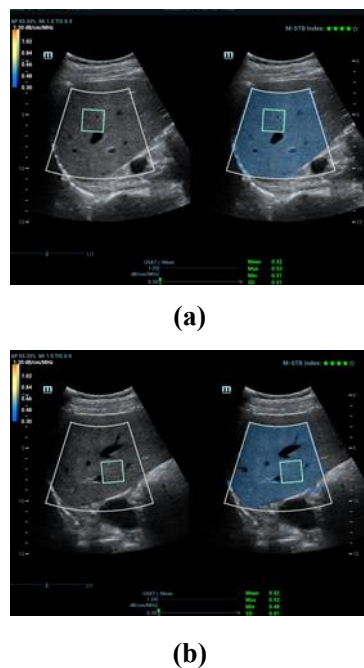


Figure 17. USAT's Stability in different views

Conclusions

Mindray USAT provides a new and easy tool that obtains ultrasound attenuation imaging and measurement to analyze and diagnose fatty liver quantitatively. Based on the innovative "Full Space Restitution Technology", USAT restitutes the real sound speed and attenuation from ultrasonic echoes that improves accuracy and reproducibility of measurements. Accurate quality control indicators help users obtain higher quality ultrasound attenuation images and measurements. Flexible and convenient research tools allow users to conduct clinical studies for various purposes, such as screening, diagnosis, and follow-up of fatty liver disease.

Despite limited samples, the findings of this preliminary clinical study have fully demonstrated the reliability and efficacy of USAT in fatty liver assessment. In addition, visual image-guided positioning and dual quality control of motion interference and reliability maps have brought potential

research value to clinical practice.

Currently, more extensive USAT clinical studies have been conducted in hospitals. More detailed recommendations and reference about clinical diagnosis could be published in the near future.

References

- [1] Asrani SK, Devarbhavi H, Eaton J, Kamath PS. Burden of liver diseases in the world. *J Hepatol* 2019, 70:151–171.
- [2] Chalasani N, Younossi Z, Lavine JE, et al. The diagnosis and management of non-alcoholic fatty liver disease: practice guideline by the American Association for the Study of Liver Diseases, American College of Gastroenterology, and the American Gastroenterological Association. *Hepatology* 2012,55:2005–2023.
- [3] Bian H, Bi YF, et al. Consensus for diagnosis and treatment of nonalcoholic fatty liver diseases and metabolic disorders (2nd Edition). *J. Clin Hepatol.* 2018, 34(10): 2103-2108
- [4] Fan JG, Wei L, Zhuang H, et al. Guidelines of prevention and treatment for nonalcoholic fatty liver disease: a 2018 update. *J Prac Hepatol.* 2018,21(2): 177-186
- [5] Ren X, Xia S, Zhang L, et al. Analysis of liver steatosis analysis and controlled attenuation parameter for grading liver steatosis in patients with chronic hepatitis B. *J. Quant Imag Med Surg.* 2021,11(2):571-578
- [6] Gatos I, Drazinos P, Yarmenitis, et al. Liver Ultrasound Attenuation: An

- Ultrasound Attenuation Index for Liver Steatosis Assessment. *J. Ultrasound Q.* 2022,38(2): 124-132
- [7] Ren X, Wang J, Xia S, et al. A new visual quantitative assessment of ultrasound attenuation parameters for the mild liver steatosis. *J. Ann Transl Med.* 2022,10(6):343
- [8] Development and Validation of a Nomogram for Prediction of the Risk of MAFLD in an Overweight and Obese Population. *J. Clinical and Translational Hepatology.* 2022
- [9] Fujiwara Y, Kuroda H, Abe T, et al. The B-Mode Image-Guided Ultrasound Attenuation Parameter Accurately Detects Hepatic Steatosis in Chronic Liver Disease. *J. Ultrasound in Medicine & Biology*, 2018, 44(11):2223-2232.
- [10] Ferraioli G, Maiocchi L, Raciti M V, et al. Detection of Liver Steatosis With a Novel Ultrasound-Based Technique. *J. Clin and Translational Gastroenterology*, 2019, 10(10).
- [11] Bae J S, Dong H L, Lee J Y, et al. Assessment of hepatic steatosis by using attenuation imaging: a quantitative, easy-to-perform ultrasound technique. *J. European Radiology*, 2019:1-9.
- [12] Jeon S K, Lee J M, Joo I, et al. Prospective Evaluation of Hepatic Steatosis Using Ultrasound Attenuation Imaging in Patients with Chronic Liver Disease with Magnetic Resonance Imaging Proton Density Fat Fraction as the Reference Standard. *J. Ultrasound in Medicine & Biology*, 2019, 45(6):1407-1416
- [13] Webb M, Yeshua H, Zelber-Sagi S, et al. Diagnostic value of a computerized hepatorenal index for sonographic quantification of liver steatosis. *J. American Journal of Roentgenology.* 2009, 192(4):909-14.
- [14] Gaitini D, Baruch Y, Ghersin E, et al. Feasibility study of ultrasonic fatty liver biopsy: texture vs. attenuation and backscatter. *J. Ultrasound in Med & Biology*, 2004, 30(10):1321-1327.
- [15] Imbault M, Faccinnetto A, Osmanski BF, et al. Robust sound speed estimation for ultrasound-based hepatic steatosis assessment. *J. Physics in Medicine & Biology*, 2017, 62(9):3582-3598.

